

**Acromio -  
clavicular  
joint  
dislocation**



5 rue de la Fontaine 21560 Arc sur Tille FRANCE  
Tél 33 03 80 37 26 60 - Fax 33 03 80 37 26 61  
E.Mail : [Lars.Sa@wanadoo.fr](mailto:Lars.Sa@wanadoo.fr)



## Principles

The acromio-clavicular dislocations damaged of the articulation of the sterno-cleïdo-scapular system, whose complex physiology regulates proper gleno-humeral function. (D. PATTE \*)

The technique using :

- The **LARS LAC 30 CK** (Ø maxi. 5 mm - Ref L400305) or **LARS LAC 20** (Ø maxi. 4 mm - Ref L400205) ligaments are made of polyester. The longitudinal fibers are assembled by a special knitting process and are therefore not very susceptible to plastic deformation. The porous structure of the ligament permits rapid fibroblastic ingrowth,
- A specially designed instrument permits passage under the coracoid through a removable canula on the other side and ascending sufficiently high up, a wire loop, to which are attached the leads of the ligament,

assures a coraco-clavicular fixation

- isolated, without transpassing the joint,
- flexible, but solid,
- simple and no damaging.

**This type of surgical intervention is reserved for joint dislocations stade III and more.**

**Note :**

Any necessary intervention at the level of the acromio-clavicular joint will be performed, if necessary, before the reduction and fixation, as in all other techniques.

\* PATTE D. : Faut-il opérer les luxations acromio-claviculaires ? 86ème Congrès Français de Chirurgie. Paris, Maloigne, 1984.

\* PATTE D. : Les luxations traumatiques des articulations acromio et sterno-claviculaires. Cahier d'enseignement

## Surgical exposure

Incision parallel to the anterior border of the clavicle or in a vertical "criss-cross", (esthetically better), directly over the coracoid, easily located by palpation. Clean the A. C. joint and remove all the fibrous tissues to allow the relocation of the clavicle.

## Trans-clavicular tunnels

Drilling of two tunnels Ø 3.5 mm (LAC 20) or Ø 4.5 mm (LAC 30 CK), **respecting the anterior and posterior cortex** (zones of mechanical strength).

The lateral tunnel is oblique, forward :

- its entrance point is situated at the junction of the superior aspect and the posterior border at about 1 cm from the acromio-clavicular joint,
- its exit point is situated at the junction of the inferior aspect and the anterior border at the insertion of the trapezoid ligament, meaning slightly outside the line of the lateral border of the coracoid.

The medial tunnel is oblique, backward :

- its entrance point is located at the junction of the anterior cortex and the superior aspect, perpendicular with the medial border of the coracoid,
- its exit hole is inferior and posterior.

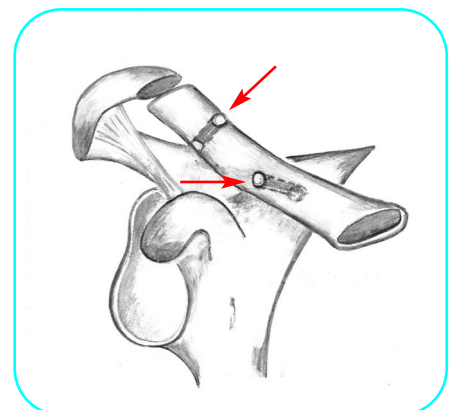
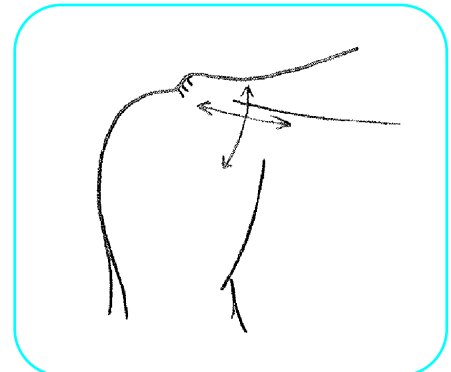
When the tunnels are drilled, a retractor is placed on the inferior aspect of the clavicle, to prevent any damage when the drill bit exits.

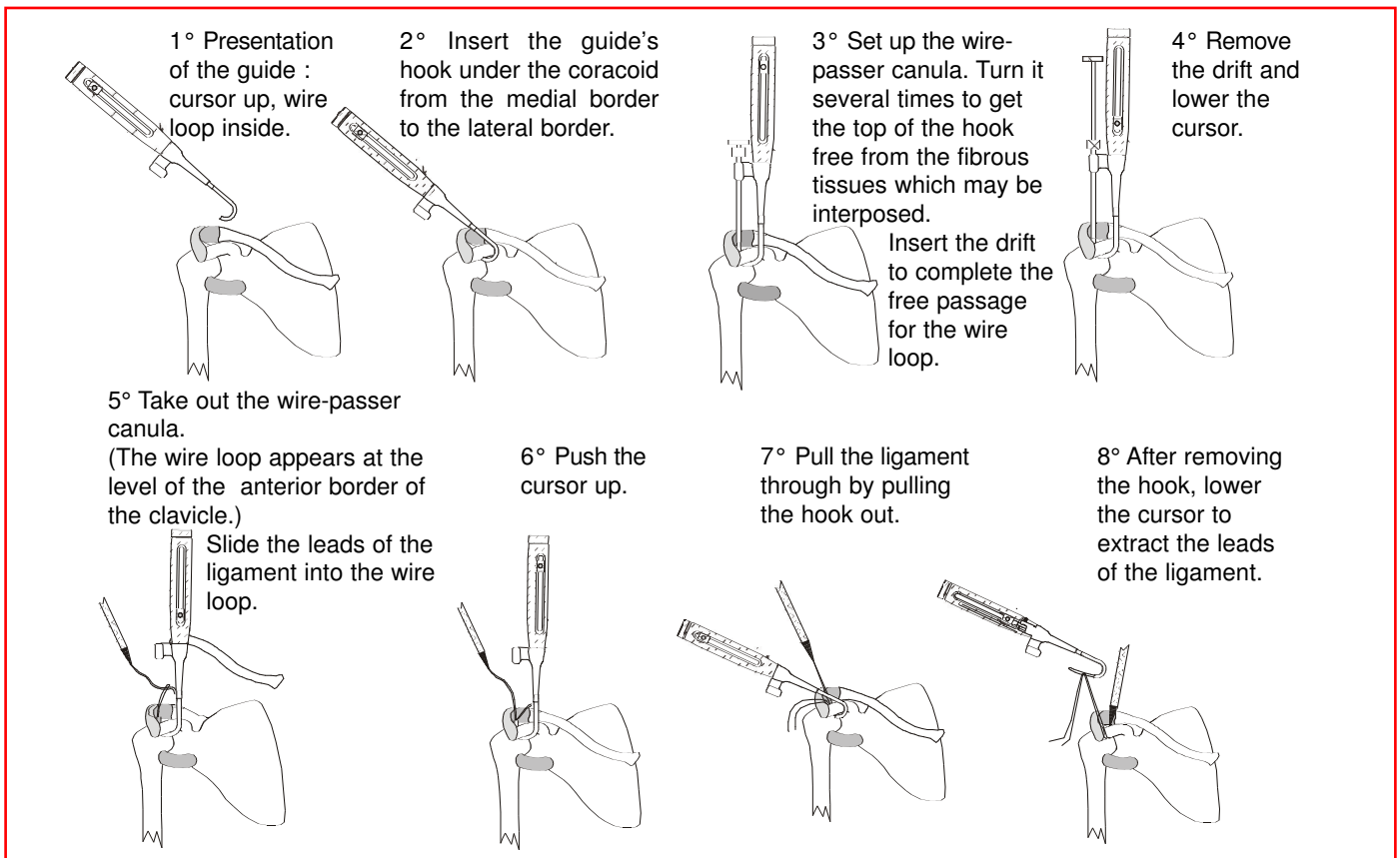
**Note :**

So to have a zone of bone with better consistency, drill the lateral tunnel at the base of the lateral border of the coracoid.

## Preparation of the passage under the coracoid

Expose, carefully, the medial and lateral border of the coracoid by incision of the "aponevrosis" and liberation with a rasp.





## Passing the ligament

The ligament is passed under the coracoid.

A wire loop, introduced into the trans-clavicular tunnel, pull the lateral ligament bundle through the lateral tunnel and the medial bundle through the medial tunnel.

The regulation of tension is done by pulling alternately on each bundle.

## Fixation with manual reduction of the clavicle

Be careful with its position in the horizontal plan.

Fixation in the bony tunnels with titanium interference screws (Ø 4.7 x 15 mm or 5.2 x 15 mm). The ends of the ligament are cut flush to the superior aspect of the clavicle, leaving no trouble some projections.

The incision is closed by suturing together the trapezo-deltoid margins, with a drain in place.

### Note : Advice for the fixation of the ligament

In case the fixation with interference screw of the lateral ligament bundle doesn't appear satisfactory, we suggest to you two possibilities ensuring a stable and lasting fixation, at once.

#### Proposal n° 1

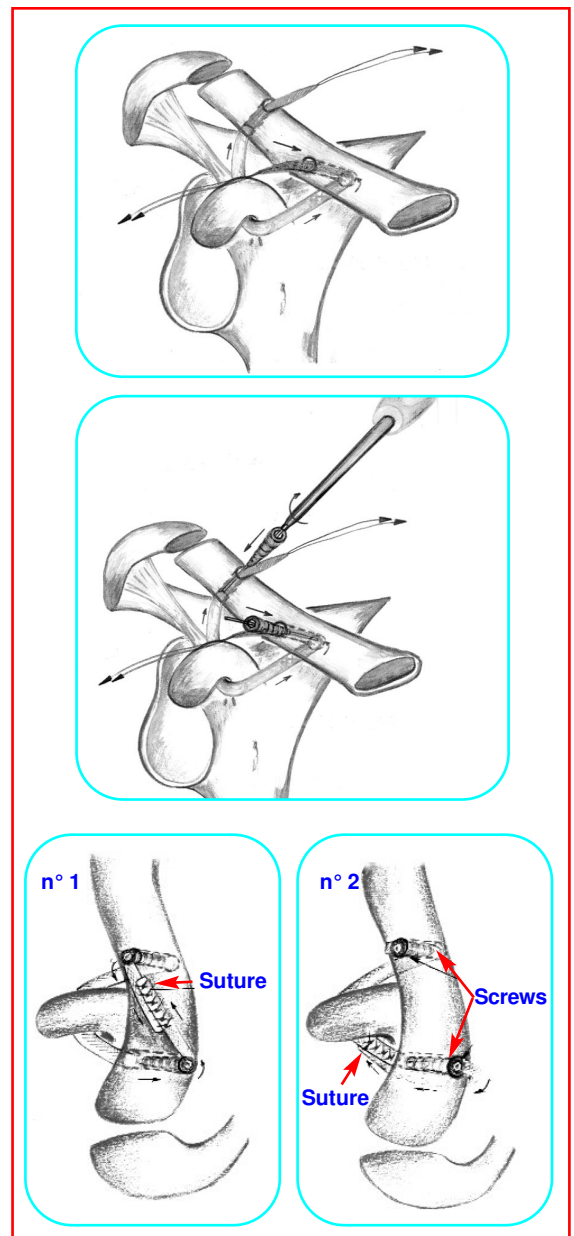
Suture along 2 cm the two superposed ligament bundles with no resorbable thread, flat against the clavicle, then cut the two extremities of the ligament, with a cold bistoury.

#### Proposal n° 2

Pass the lateral ligament bundle behind and below the clavicle, then suture with no resorbable thread this same bundle to the ligament going up from the lateral border of the coracoid.

## Post operative care

- splint with elbow against the body the first few days,
- active mobilization of the shoulder as of the 5th day,
- back to work and sport authorized after the 4th week.





**Certified company**  
**in compliance with the requirements**  
**of the international standard**  
**NF EN ISO 13485**  
**93 / 42 EEC**

